

Use of Single Forearm Incision for Tendon Transfer for Radial Nerve Palsy: Prospective Study

Wael N. Thabet, M.D.*; Mostaf Mahmoud, M.D.** and Joseph N. Thabet, M.D.***

The Departments of Surgery*, Orthopaedics** and Anatomy***, Faculty of Medicine, Cairo University

ABSTRACT

Loss of radial nerve function in the hand creates a significant disability. The patient cannot extend the fingers and thumb and has great difficulty in grasping objects. Perhaps more importantly, the loss of active wrist extension robs the patient of the mechanical advantage that wrist extension provides for grasp and power grip. Tendon transfer using a single incision in its place can solve these problems in short time.

Key Words: Radial nerve palsy – Tendon transfer – Single incision.

INTRODUCTION

The radial nerve arises from the posterior cord of the brachial plexus. The radial nerve enters the upper posterior brachium and passes through a triangular space that is bordered superiorly by the teres major muscle, laterally by the humerus, and medially by the long head of the triceps muscle. Accompanied by the profunda brachii artery, the nerve enters the musculospiral groove between the medial and lateral heads of the triceps [1].

The nerve crosses the humerus posteriorly from proximal medial to distal lateral. Throughout its course posterior to the humerus, the nerve gives off branches to the lateral and medial heads of the triceps and to the lower lateral brachial cutaneous nerve. After passing around the lateral aspect of the humerus and piercing the lateral intermuscular septum, the radial nerve enters the interval between the brachialis and brachioradialis muscles [1].

Near the level of the lateral epicondyle of the humerus, the nerve bifurcates into the superficial and deep branches. The superficial branch of the radial nerve continues distally beneath the brachioradialis muscle, until it passes between the tendons of the brachioradialis and the ECRL, approximately 9 cm proximal to the radial styloid [2,3].

Distally, it arborizes to provide sensory innervation to the dorsoradial aspect of the hand, thumb, index finger, and, variably, the long and ring fingers. Occasionally in some

patients the superficial branch of the radial nerve is absent and its function is preempted by the lateral antebrachial cutaneous nerve [3].

The deep radial nerve branch, or posterior interosseous nerve, passes beneath recurrent vessels from the radial artery and then, approximately 5 cm distal to the lateral humeral epicondyle, enters the supinator muscle underneath the arcade of Frohse. The arcade of Frohse is the proximal margin of the supinator. Its morphology can vary from a muscular to a tendinous quality. This arcade is fibrous in about one-third of cases and may compress the nerve [2,4,5].

The nerve winds around the neck of the radius between the two heads of the supinator. In 25% of cases it lies against the periosteum for about 3cm (bare area) when the forearm is supinated; it is more vulnerable at this level. Multiple branches innervate the supinator as the nerve traverses beneath it [4,5].

As the posterior interosseous nerve emanates from the distal margin of the supinator, branches exit to supply the extensor digitorum communis (EDC), the extensor digiti quinti (EDQ), and the extensor carpi ulnaris (ECU). The remaining trunk of the posterior interosseous nerve continues distally in the interval between the extensor pollicis longus (EPL) and the abductor pollicis longus (APL) [5].

One branch exits the nerve to branch again to innervate the abductor pollicis longus (APL) and extensor pollicis brevis (EPB), another branch emanates from the nerve and subdivides to supply

45

the extensor indicis proprius (EIP) and the extensor pollicis longus (EPL), and the remainder of the nerve continues distally to the wrist joint [5].

The functional deficits in the upper extremity after a radial nerve injury involve the wrist, finger, and thumb extensors. Traditionally, radial nerve palsy has been

categorized into high and low types. High palsy refers to a radial nerve injury that is proximal to the elbow and that results in deficits in wrist and digital extension. Low palsy refers to denervation of muscles that are innervated by the PIN, thus sparing wrist extension, with deficits in thumb and finger extension. As the ECU is denervated in a low palsy, wrist extension occurs in a dorsoradial direction [6].

In a high radial nerve palsy, aside from the obvious inability to extend the digits or wrist, poor grasp is a major functional complaint. After radial nerve block in volunteers, grip strength decreased by 77% [6].

The etiology of radial nerve palsy in the brachium is usually direct or indirect trauma. Penetrating trauma can variably affect a nerve. Sharp lacerations usually result in nerve transection, whereas gunshot wounds often result in neuropraxia or axonotmesis and, rarely, neurotmesis [10].

In most series of supracondylar humeral fractures in children, the radial nerve is the most commonly injured nerve, especially when the distal fragment is displaced posteromedially [11,12].

Palsy from compression of the Posterior interosseous nerve (PIN) by a mass, such as a ganglion cyst or synovitis that arises from the elbow joint, has also been reported [13,14]. Nerve entrapment can occur in the radial tunnel in which the nerve underlies unyielding fascial structures, most commonly, the arcade of Frohse or bands within the supinator muscle [14].

Tendon transfer was first used by Nicoladoni in 1880 in Vienna, then Codovilla (1899) and Lange in 1900 introduced this type of surgical treatment for motor paralysis of the upper limb. The general principles have been gradually set down through the works of others [15-24].

Nowadays, the need for tendon transfers is less frequently due to constant improvements in the quality of nerve sutures. However, the increased occurrence of traumatic avulsions and ballistic lesions has led to the same levels of requirement for restoration of function as before. These procedures have to be adapted for each patient according to the remaining motor muscles [15].

Regarding the level of the lesion, tendon transfers have to restore function that has been lost and not the function of one paralyzed muscle [15].

Tendon transfers are indicated after 6-18 months according to which nerve injured, if no clinical and electrical reinnervation occurs after suture, or when

nerve repair has failed or when the nerve is irreparable [15].

Profession, age, the use of a partially paralyzed dominant hand, functional substitutes, associated lesions and the cause of the palsy are important. Each element of the procedure as regards the motor muscle, tendon path, and tendon fixation must be adapted to each case [15].

PATIENTS AND METHODS

In prospective analysis, A total of 18 patients of radial nerve injury (17 men and 1 woman) with a mean age of 30 years (range, 22-40 years) underwent tendon transfer after failed nerve reconstruction. The exclusion criterion was radial nerve dysfunction resulting from brachial plexus injury.

A- Preoperative management protocol:

1- History taking and clinical examination:

- *Personal data:* (name, sex, age, date of birth, special habits of medical importance, residency, occupation, telephone number and handedness).
- *Age:* The mean age of the patient population was 30 years. Our youngest patient was 22 years old and the oldest was 40 years.
- *Sex:* 17 patients were males and 1 patient was female.
- All our patients are right handed.
- History of previous related operation and precise examination of its results are recorded.

2- Mode and date of trauma:

- In 10 cases, the cause of the initial radial nerve injury was a humeral shaft fracture; in 5 cases, the cause was a gunshot injury; and in 3 cases, the cause was an iatrogenic injury during surgical procedures in arm. Table (1) shows causes of Injury in descending order of occurrence.
- Time of surgery following initial trauma was recorded.

Table (1): Causes of injury in descending order of occurrence.

Cause of injury	Number of cases
Humeral shaft fracture	10
Gunshot injuries	5
Iatrogenic caused lesion	3

3- Clinical examination:

- A detailed examination of the injured extremity looking for scars, joint mobility, muscle power and any possible nerve recovery.
- The median, ulnar, and radial nerves were evaluated by examining finger and wrist motion looking for any associated injuries.

- Function of all possible donor muscles was estimated using the clinical examinations for the different muscle groups of the forearm.
- Hand grip strength of contralateral side using Jamar dynamometer (Jamar Hydraulic Hand Dynamometer; Sammons Preston Patterson Medical Products, Inc., Bolingbrook, IL).
- Active and passive range of motion of wrist, MCP joints and finger joints were recorded.
- A vascular examination was also performed. This examination included feeling distal pulses, feeling for thrills, or listening for bruits especially in penetrating injuries.

4- Investigations:

- Routine immediate preoperative labs included: Complete blood picture, kidney profile, liver profile, random blood sugar, and (PT, PC, INR).
- EMG and NCS studies:
 - A baseline examination, whenever possible was done 3 to 4 weeks after the traumatic injury to allow wallerian degeneration to occur and the electrodiagnostic study to reflect the nerve injury.
 - Whenever possible, a follow-up study was performed at 3 then 6 months after the initial study to assess for recovery.

B- Surgical technique:

- Indication of surgery:

Patients with no hope for spontaneous recovery, after failed nerve reconstruction, because nerve reconstruction was contraindicated due to extensive scars, very long defects >10cm or in old age patients (>60 years) with inferior results of repair.

- Timing of surgery:

All cases were operated upon between 6-18 months of injury (mean 12m) after their injury if they had no evidence of recovery and had electrophysiological evidence of no regeneration after at least 6 months or from the start if there's irreparable nerve injury.

- Informed consent:

The possible surgical options, risk-benefit ratio, postoperative rehabilitation program and outcome with or without surgery were discussed in detail with the patient and his or her family. They need to have realistic expectations and a clear understanding of the goals and priorities of the planned surgery.

- Surgical technique:

For all tendon transfer procedures, critical components of the procedure include intraoperative confirmation of the ROM of all joints will be used and confirmation of appropriate donor muscles selection. With the patient supine after application of tourniquet, a 10cm long incision is first marked over the radial aspect of the forearm (Fig. 1) extending from the middle third of the radial side of the forearm to 1cm proximal to the radial styloid distally. All the tendons required for the transfer are explored and identified through the same incision (Figs. 2,3). By good retraction of the wound proximally, Pronator teres muscle is raised from its insertion with a 4cm sleeve of periosteum.

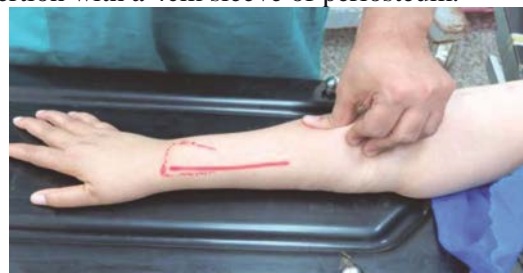

Fig. (1): Incision marking.

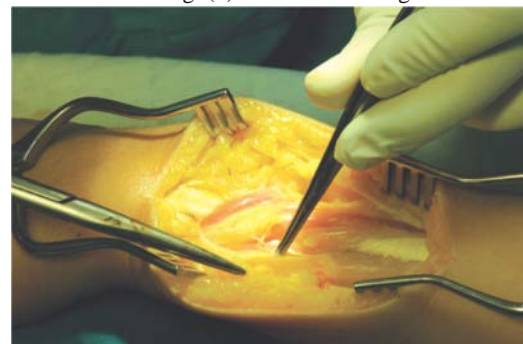


Fig. (2): The tendons required for the transfer are explored.

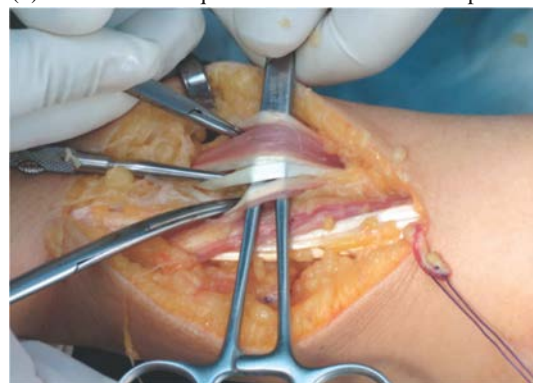

Fig. (3): Tendons required for the transfer are explored and identified.

The pronator teres tendon is passed subcutaneously around the radial border of the forearm, superficial to the brachioradialis and extensor carpi radialis longus to reach the musculotendinous junction of extensor carpi radialis brevis muscle. The palmaris longus and the flexor carpi radialis tendons are identified and

transected at the level of the wrist. Both tendons are identified at a higher level through the same incision and pulled up proximally.

The flexor carpi radialis tendon is passed around the radial border of the forearm to reach the extensor digitorum communis tendons at the lower third of the forearm (Fig. 4). Extensor pollicis longus tendon is divided at the musculotendinous junction and rerouted to the radial side of lister tubercle. Now the tendon anastomosis are carried out one by one tension is in maximum degree of desired range and as far distal as the donor tendon allow using end to side maneuver in both extensor of wrist and fingers while end to end with PL to EPL., followed by suturing of flexor carpi radialis tendon to extensor digitorum communis tendons, and finally, the palmaris longus tendon is sutured to the extensor pollicis longus tendon (Fig. 5). Pronator teres is sutured to the extensor carpi radialis brevis tendon (Fig. 6).

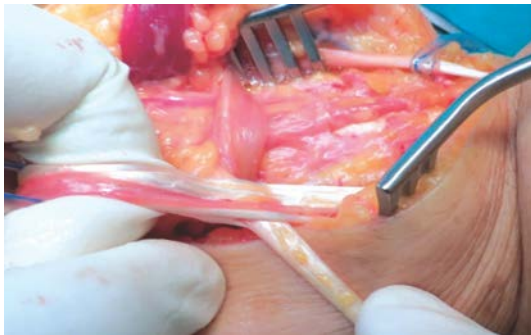


Fig. (4): Flexor carpi radialis to extensor digitorum communis.

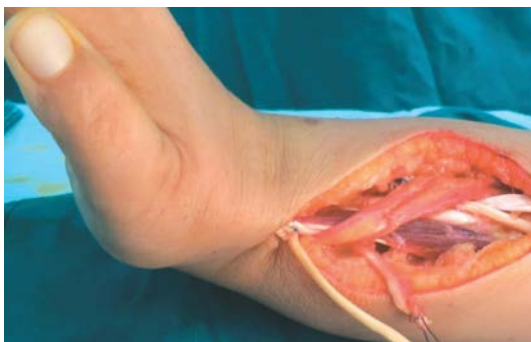

Fig. (5): Palmaris longus to extensor pollicis longus transfer.

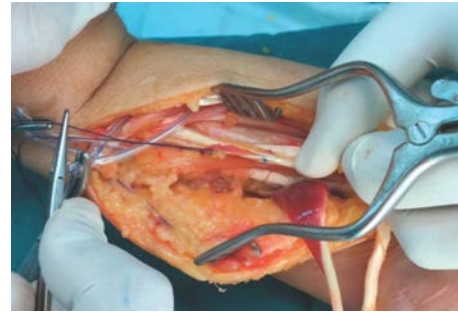

Fig. (6): Pronator teres to extensor carpi radialis brevis.

All sutures are made with 3-0 or 4-0 polypropylene with 5/8 rounded tip needles. In 2 cases where the palmaris longus tendon was absent, we used the flexor digitorum superficialis of the long finger. The wound is closed with subcuticular sutures after obtaining hemostasis after tourniquet deflation.

C- Postoperative management protocol:

All patients are given an above elbow plaster holding the wrist in 30-40 degrees of dorsiflexion, metacarpophalangeal and PIP joints in full extension, and the thumb in maximum radial abduction and extension. This position is maintained for a period of 2 weeks followed by freeing the PIP joints to move and continue the slab for more 2 weeks then another 2 weeks with the wrist in neutral position and freeing the MCP joints to move, then supervised exercise program after slab was discarded. A below elbow night splint is used for another 3 weeks maintaining the same position. With all above maneuver care must be taken to encourage joint mobility of shoulder and elbow as well.

The standardized follow-up focused on the extent of motion determined through the neutral zero method with active and passive range of motion of wrist, MCP joints and finger joints were recorded.

In addition, we measured grip strength using a Jamar dynamometer (Jamar Hydraulic Hand Dynamometer; Sammons Preston Patterson Medical Products, Inc., Bolingbrook, IL) with reference to contralateral side grip strength and to standardized scores (Fig. 7).



Fig. (7): Jamar dynamometer.

In addition, we evaluated:

- The number of patients employed postoperatively.
- The scar regarding its appearance, adherence, width, elevation, flexibility and presence of signs of infection is done.
- Path of transferred tendons is also examined for adhesions, tenderness and any crepitations.
- Functional results were assessed using a quickDASH scoring system.
- Patient satisfaction assessment with a two simple questions, first is, if he is satisfied or not and the second is, his agreement to do the same procedure to his other limb if it gained the same injury or not, with explanation, were done.

- Wrist flexion 0-90 degrees.
- Wrist extension 0-70 degrees.
- Wrist abduction 0-25 degrees.
- Wrist adduction 0-65 degrees.
- MCP flexion 0-90 degrees.
- MCP extension 0-30 degrees.
- Interphalangeal proximal (PIP) joints of fingers flexion 0-120 degrees.
- PIP extension 120-0 degrees.
- Interphalangeal distal (DIP) joint of fingers flexion 0-80 degrees.
- DIP extension 80-0 degrees.

- Metacarpophalangeal joint of thumb abduction 0-50 degrees.
- MCP of thumb adduction 40-0 degrees.
- MCP of thumb flexion 0-70 degrees.
- MCP of thumb extension 60-0 degrees.
- Interphalangeal joint of thumb flexion 0-90 degrees.
- Interphalangeal joint of thumb extension 90-0 degrees.

Fig. (8): Normal wrist and hand joints range of motion.

RESULTS

After surgical treatment, the average ranges of wrist movement were as follows: Mean extension was $56^{\circ} \pm 5^{\circ}$, which was 85% of the maximum mobility of the opposite side. Mean flexion was $57^{\circ} \pm 5^{\circ}$, equivalent to 75% of the maximum degree of movement of the healthy side. Radial deviation was $17^{\circ} \pm 5^{\circ}$, and ulnar deviation was $55^{\circ} \pm 5^{\circ}$. The mean finger extension during wrist extension was $75^{\circ} \pm 5^{\circ}$ and was almost similar in the wrist neutral position at $75^{\circ} \pm 5^{\circ}$. The mean palmar abduction of

grip strength of 25 ± 2 kg; the average of the healthy opposite side was 37 ± 2 kg (Fig. 10). After their tendon transfer, 14 patients still continue their previous carrier, 4 were unemployed changing their carrier from being heavy manual workers to lighter work to satisfy their new functions.

All patients achieved a mean pronation of $80^{\circ} \pm 10^{\circ}$ and a mean supination of $70^{\circ} \pm 10^{\circ}$, which amounts to a 12% restriction compared with the contralateral healthy hand.

Regarding scar assessment we were not encountered any case of infection, scar adhesions or abnormally shaped scars (Fig. 12).

All our patients were satisfied with procedure with no refusal to do same operation if they had

same injury to his healthy limb even with the patient who developed the SRN neuroma, sure after its excision.

Only one postoperative complication is encountered, which is superficial radial nerve neuroma which developed to the patient after 5 months from tendon transfer surgery and 11 months from initial attempt of radial nerve repair which is probably due to SRN injury during exploration of PT muscle at upper part of the wound. And this annoying complication required another small operation to excise the neuroma.

the thumb was $41^{\circ} \pm 5^{\circ}$, which was 80% of the maximum mobility of the opposite side (Fig. 9).

We evaluated hand grip strength using a Jamar dynamometer. On average, the operated hand had

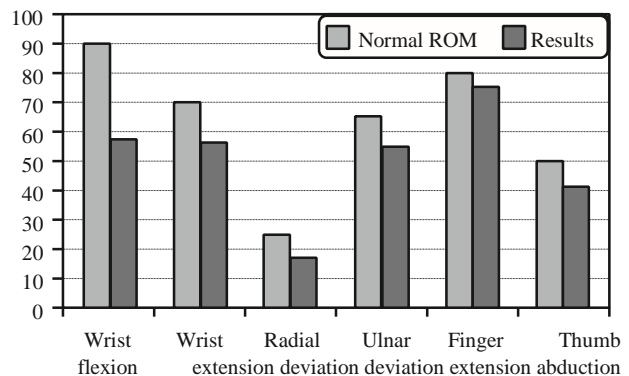


Fig. (9): Range of motion postoperatively between both sides.

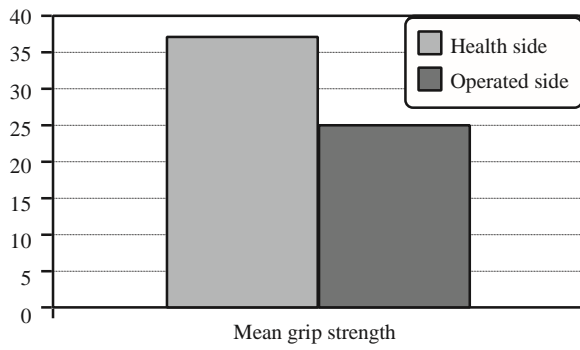


Fig. (10): Mean grip strength.

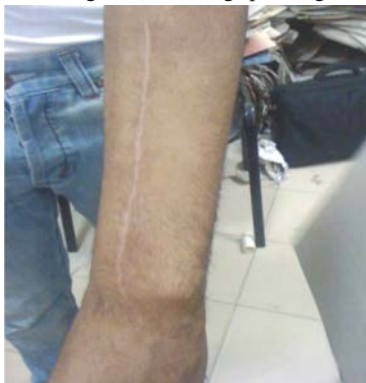

Fig. (11): Postoperative wound closure with subcuticular sutures.

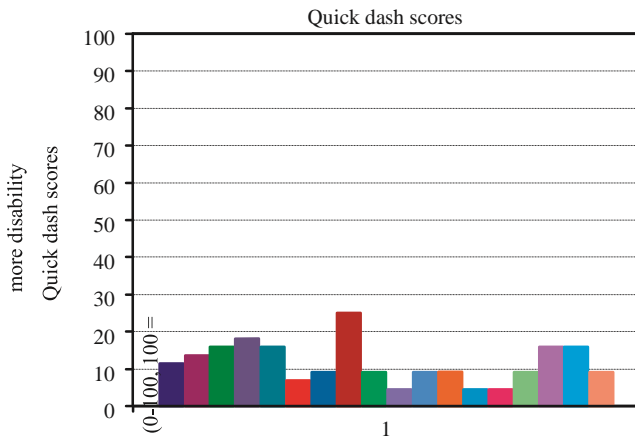
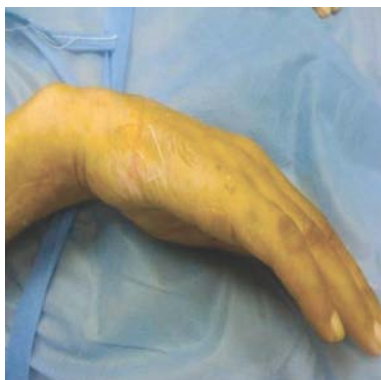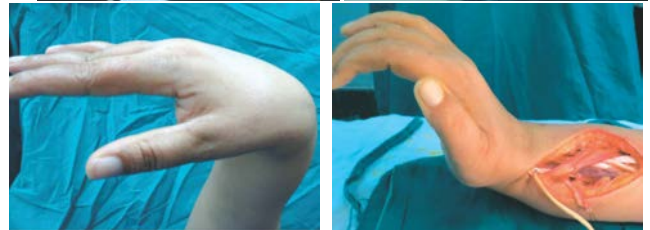

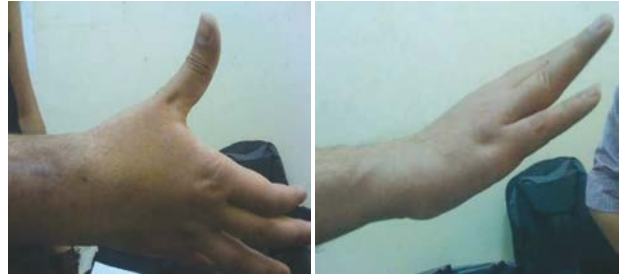
Fig. (12): Postoperative dash (Dash = Disability of arm, shoulder and hand).



Case (1): Preoperative.



Case (2): Preoperative.

Case (2): Intraoperative.

Table (2): Normal power grip strength in different age groups viewed in pounds. One kilogram is equivalent to 2.2 pounds.

Age	Hand	Males		Females	
		Mean	SD	Mean	SD

6-7	R	32.5	4.8	28.6	4.4
	L	30.7	5.4	27.1	4.4
8-9	R	41.9	7.4	35.3	8.3
	L	39.0	9.3	33.0	6.9
10-11	R	53.9	9.7	49.7	8.1
	L	48.4	10.8	45.2	6.8
12-13	R	58.7	15.5	56.8	10.6
	L	55.4	16.9	50.9	11.9
14-15	R	77.3	15.4	58.1	12.3
	L	64.4	14.9	49.3	11.9
16-17	R	94.0	19.4	67.3	16.5
	L	78.5	19.1	56.9	14.0
18-19	R	108.0	24.6	71.6	12.3
	L	93.0	27.8	61.7	12.5
20-24	R	121.0	20.6	70.4	14.5
	L	104.5	21.8	61.0	13.1
25-29	R	120.8	23.0	74.5	13.9
	L	110.5	16.2	63.5	12.2
30-34	R	121.8	22.4	78.7	19.2
	L	110.4	21.7	68.0	17.7
35-39	R	119.7	24.0	74.1	10.8
	L	112.9	21.7	66.3	11.7
40-44	R	116.8	20.7	70.4	13.5
	L	112.8	18.7	62.3	13.8
45-49	R	109.9	23.0	62.2	15.1
	L	100.8	22.8	56.0	12.7
50-54	R	113.6	18.1	65.8	11.6
	L	101.9	17.0	57.3	10.7
55-59	R	101.1	26.7	57.3	12.5
	L	83.2	23.4	47.3	11.9
60-64	R	89.7	20.4	55.1	10.1
	L	76.8	20.3	45.7	10.1
65-69	R	91.1	20.6	49.6	9.7
	L	76.8	19.8	41.0	8.2
70-74	R	75.3	21.5	49.6	11.7
	L	64.8	18.1	41.5	10.2
75+	R	65.7	21.0	42.6	11.0
	L	55.0	17.0	37.6	8.9

Case (1): 6 months postoperative.

Table (3): Preoperative dash score

Patient	Time	Jar (item 1)	Heavy household (item 2)	Carrying shopping bag (item 3)	Wash your back item 4) (i (Cut your food tem 5)	Recreational activities (item 6)	Social activities (item 7)	Work			Quick dash score
									regular activities (item 8)	Pain (item 9)	Tinging (item 10)	

1	6 months	4	3	4	3	4	4	4	4	3	5	4	
2	6 months	4	2	2	3	3	3	5	5	3	3	3	70.5
3	6 months	3	2	3	4	3	4	3	4	3	5	3	56.8
4	6 months	5	4	5	3	4	5	4	5	4	5	2	59.1
5	6 months	4	4	4	4	4	3	5	3	4	5	2	79.5
6	6 months	3	5	4	4	3	3	5	3	4	4	2	70.5
7	6 months	3	3	3	3	3	2	3	2	5	5	2	65.9
8	6 months	3	4	3	3	3	4	5	2	1	1	2	52.3
9	6 months	5	5	5	3	5	5	4	3	5	5	2	45.5
10	6 months	4	4	5	3	4	5	5	3	5	5	2	81.8
11	6 months	5	3	3	4	5	4	4	2	4	5	2	77.3
12	6 months	4	4	3	3	3	4	5	2	4	5	2	68.2
13	6 months	4	5	4	3	4	3	5	1	4	5	1	63.6
14	6 months	3	4	5	4	4	5	5	1	5	5	1	63.6
15	6 months	4	3	4	5	3	4	5	3	4	4	1	70.5
16	6 months	5	3	5	4	3	4	4	3	4	5	2	65.9
17	6 months	5	3	3	4	3	4	4	5	4	5	1	70.5
18	6 months	3	4	3	3	4	4	4	4	4	5	1	68.2
45678gt													72.7
													Not enough data
													Not enough data
													Not enough data
Average for your sample	n/a	3.9	3.6	3.8	3.5	3.6	3.9	4.4	3.1	3.9	4.6	2.2	66.8

Table (4): Postoperative dash score

Patient	Time	Jar (item 1)	Heavy household (item 2)	Carrying shopping bag (item 3)	Wash your back (item 4)	Cut your food (item 5)	Recreational activities (item 6)	Social activities (item 7)	Work regular activities (item 8)	Pain (item 9)	Tinging (item 10)	Sleep (item 11)	Quick dash score
1	5 months	1	2	1	1	1	2	2	3	1	1	1	11.4
2	5 months	1	2	1	1	1	2	2	4	1	1	1	13.6
3	5 months	2	2	1	1	1	2	2	4	1	1	1	15.9
4	5 months	1	2	2	1	1	2	2	5	1	1	1	18.2
5	5 months	2	2	2	1	1	2	2	3	1	1	1	15.9
6	5 months	1	1	2	1	1	1	1	3	1	1	1	6.8
7	5 months	1	2	1	1	1	1	2	2	1	1	2	9.1
8	5 months	1	1	1	1	1	2	1	3	4	4	3	25.0
9	5 months	1	2	1	1	1	2	1	3	1	1	1	9.1
10	5 months	1	1	1	1	1	1	1	3	1	1	1	4.5
11	5 months	2	2	1	1	1	2	1	2	1	1	1	9.1
12	5 months	1	2	2	1	2	1	1	2	1	1	1	9.1
13	5 months	1	2	1	1	1	1	2	1	1	1	1	4.5
14	5 months	2	1	1	1	1	1	2	1	1	1	1	4.5
15	5 months	1	2	1	2	1	1	1	3	1	1	1	9.1
16	5 months	2	3	1	1	1	2	2	3	1	1	1	15.9
17	5 months	1	3	2	2	1	2	1	3	1	1	1	15.9
18	5 months	1	1	1	1	1	2	1	4	1	1	1	9.1
45678gt													
													Not enough data
													Not enough data
													Not enough data

Average for your sample	n/a	1.3	1.8	1.3	1.1	1.1	1.6	1.5	2.9	1.2	1.2	1.2	11.5
-------------------------------	-----	-----	-----	-----	-----	-----	-----	-----	-----	-----	-----	-----	------

DISCUSSION

Loss of radial nerve function in the hand creates a significant disability. The patient cannot extend the fingers and thumb and has great difficulty in grasping objects. Perhaps more importantly, the loss of active wrist extension robs the patient of the mechanical advantage that wrist extension provides for grasp and power grip. The first decision to make in a patient with an established radial nerve palsy is whether to attempt late repair of the nerve or to restore lost function with tendon transfers [23].

Tendon transfers to restore function in radial nerve palsy are among the best and most predictable transfers in the upper extremity. The appropriate time to perform transfers for radial nerve palsy is a somewhat controversial subject. As noted previously, several authors [7-9,18,24].

Brown [24] suggested that it is advisable to proceed with the full component of tendon transfers early when there is a questionable or poor prognosis from the nerve repair. For example, if there is a nerve gap of more than 4cm or if there is a large wound or extensive scarring or skin loss over the nerve, he recommended ignoring the nerve and proceeding directly to the tendon transfers. Recently most of authors basically agree with Brown, as if the chances of nerve regeneration are poor, there is no point in waiting before doing the transfers.

In our study we went in favour with using the ECRB as a recipient muscle because that the ECRL takes its origin at the supracondylar ridge of the humerus, it plays a role in elbow flexion and loses a part of its wrist action when the elbow is flexed. In contrast, the ECRB has its origin on the epicondyle and is not affected by the position of the elbow, all of its action is on the wrist. These two tendons are congruent along most of their length in the forearm, however, they diverge at the wrist level so that at their insertions the ECRL tendon is about 1.5cm lateral to the ECRB. The moment arms for extension of the wrist are 16.30mm for the ECRB and only 12.50mm for the ECRL (Ketchum et al., 1978) [7]. In the ECRL the moment arm for elbow flexion and radial deviation is more important than that for wrist extension; the ECRL

only becomes a wrist extensor after radial deviation is balanced against the ulnar forces of the ECU which is paralyzed. Thus the two wrist extensors have very different moment arms of extension. The ECRB is the most effective extensor of the wrist.

Recent studies by M. Ropars et al., using either FCR or FCU and comparing between them in his results. He stated that the choice between these two tendons remains controversial (Bincaz et al., 2002; Dunnet, 1995; Ketchum et al., 1978; Raskin and Wilgis, 1995; Tubiana, 1991). FCU is the stronger flexor of the wrist. It is also stronger than the EDC and has the advantage of a longer excursion than FCR.

In his study, mean wrist flexion of the clenched fist was 28 (range 0-60) degrees. This mean measurement was 41 degrees when the FCR was transferred and 21 degrees when the FCU was transferred. Wrist flexion with the hand open was 35 (range 0-60) degrees. Average wrist extension was 38 (range 10-60) degrees with the metacarpophalangeal joints flexed and 34 (range 10-70) degrees with the metacarpophalangeal joints extended. Pronation and supination were 83 (range 60-90) degrees and 70 (range 20-90) degrees, respectively. No abnormality of finger flexion was detected in any case. However, three patients presented with a mean loss of metacarpophalangeal joint extension of 15 (range 10-25) degrees with the wrist in the neutral position and 27 (20-30) degrees with the wrist in full extension. The other 12 patients all had full MCP extension. Ability to extend each finger independently was noted in 11 patients. Mean abduction of the thumb was 54 (range 0-70) degrees [27].

Our results are comparable with results of recently published studies in respect to range of motion, grip power strength and functional outcomes for whom used same as our transfer combination and superior for who used other combinations, but regarding to cosmetic satisfaction of the patient, our recently introduced approach with a 10cm single radial, dorsal, linear incision when compared to that of other procedures is superior.

So we recommend to use our technique in patients with no hope for spontaneous recovery or

for further recovery if any, after failed nerve reconstruction or because nerve reconstruction was contraindicated due to extensive scars, very long defects >10cm or in old age patients (>60 years) with inferior results of repair.

REFERENCES

- 1- Gerwin M., Hotchkiss R.N. and Weiland A.J.: Alternative operative exposures of the posterior aspect of the humeral diaphysis. *J. Bone Joint Surg.*, 78: 1690-1695, 1996.
- 2- Abrams R.A., Zeits R.J., Leiber R.L., et al.: Anatomy of the radial nerve motor branches in the forearm. *J. Hand Surg.*, 22: 232-237, 1997.
- 3- Abrams R.A., Brown R.A. and Botte M.J.: The superficial branch of the radial nerve: An anatomical study with surgical implications. *J. Hand Surg.*, 17: 1037-1041, 1992.
- 4- Spinner M.: The arcade of Frohse and its relationship to posterior interosseous nerve paralysis. *J. Bone Joint Surg.*, 50: 809-812, 1968.
- 5- Thomas S.J., Yakin D.E., Parry B.R., et al.: The anatomical relationship between the posterior interosseous nerve and the supinator muscle. *J. Hand Surg.*, 25: 936-941, 2000.
- 6- Labosky D.A. and Waggy C.A.: Apparent weakness of median and ulnar motors in radial nerve palsy. *J. Hand Surg.*, 11: 528-533, 1986.
- 7- Ketchum L.D., Thomson D. and Pocock G.S.: The determination of moments for extension of the wrist generated by muscles of the forearm. *J. Hand Surg.*, 3: 205-210, 1978.
- 8- Napier J.R.: Prehensile movements of the human hand, *J. Anat.*, 89: 564, 1955.
- 9- Sunderland and Sunderland S: Factors influencing the course of regeneration and the quality of the recovery after nerve suture. *Brain.*, 75: 19, 1952.
- 10- Omer G.E.: Injuries of the nerves to the upper extremities. *J. Bone Joint Surg.*, 56: 1615-1624, 1974.
- 11- Culp R.W., Osterman A.L., Davidson R.S., et al.: Neural injuries associated with supracondylar fractures of the humerus in children. *J. Bone Joint Surg.*, 72: 1211-1215, 1990.
- 12- Dutkowsky J.P. and Kasser J.R.: Nerve injury associated with fractures in children. In: Gelberman RH, ed. *Operative nerve repair and reconstruction*. Philadelphia: JB Lippincott Co., 635-653, 1991.
- 13- Ishikawa H. and Hirohata K.: Posterior interosseous nerve syndrome associated with rheumatoid synovial cysts of the elbow joint. *Clin. Orthop.*, 254: 134-139, 1990.
- 14- Millender L.H., Nalebuff E.A. and Holdsworth D.E.: Posterior interosseous nerve syndrome secondary to rheumatoid synovitis. *J. Bone Joint Surg.*, 46: 375-377, 1973.
- 15- *Surgery of Disorders of Hand and Upper Extremity*, Edited by Raoul Tubiana MD FRCS (Ed) Hon and Alain Gilbert MD, Taylor & Francis publisher, ISBN, 1-85317-494-7 (Print Edition), 2005.
- 16- Nicoladoni C.: Ein vorschlag zur sehnennaht, *Wien. Med. Wochenschr.*, 30: 144, 1880.
- 17- Codovilla A.: Sui trapianti tendinei nella pratica orthopedia, *Archivo d'Orthopedia*, 16: 225, 1899.
- 18- Biesalski K. and Mayer L.: *Die physiologische sehnervenpflanzung* (Springer: Berlin), 330, 1916.
- 19- Steindler A.: Tendon transplantation in the upper extremity, *Am. J. Surg.*, 44: 260, 1939.
- 20- Bunnell S.: *Surgery of the Hand*, 2nd edn (JB Lippincott: Philadelphia), 1948.
- 21- Boyes J.H. Tendon transfer for radial paralysis. *Bull. Hosp. Joint Dis.*, 21: 97-105, 1960.
- 22- Boyes J.H.: *Bunnell's surgery of the hand*, 5th edn. (JB Lippincott: Philadelphia), 409, 1970.
- 23- Tubiana R.: Anatomic and physiologic basis for the surgical treatment of paralysis of the, 1969.
- 24- Brand P.W.: *Clinical mechanics of the hand* (CVMosby: St Louis), 1985.
- 25- Labosky D.A. and Waggy C.A.: Apparent weakness of median and ulnar motors in radial nerve palsy. *J. Hand Surg. (Am.)*, 11: 528-533, 1986.
- 26- Brown P.W.: The time factor in surgery of upper-extremity peripheral nerve injury. *Clin. Orthop.*, 68: 14-21, 1970.
- 27- M. Ropars, et al.: Long-term results of tendon transfers in radial and posterior interosseous nerve paralysis, *Journal of Hand Surgery (British and European Volume)*, 31B: 5: 502-506, 2006.
- 28- Fuss F.K. and Wurzl G.H.: Radial nerve entrapment at the elbow: Surgical anatomy. *J. Hand Surg.*, 16: 742-747, 1991.